

**Authors: Jane Parker**, PCN Tissue Viability Specialist Nurse, West Norfolk Coastal & Kings Lynn PCN's  
Email: jane.parker34@nhs.net Tel. 07496399884.

**Rachel Sweeney**, Lead Tissue Viability Specialist Nurse & Clinical Lead Community Skin Integrity Team (West), Norfolk Community Health and Care NHS Trust.

**Sara Burr**, Community Dermatology Specialist Nurse, Skin Lesions Service, Vida Healthcare.

## INTRODUCTION

Squamous cell carcinoma (SCC) of the skin is the second most common form of skin cancer, characterised by abnormal, accelerated growth of squamous cells. SCC occurs when DNA damage from exposure to ultraviolet radiation or other damaging agents trigger changes in the squamous cells. SCCs can appear as scaly red patches, open erosions, rough, thickened or raised growths with a central depression. Untreated SCCs can become invasive, grow into deeper layers of skin and spread to other parts of the body (Venables et al 2013-2015). As a multidisciplinary team we set out to evaluate an innovative Bioactive Microfibre (BMG™) dressing (MaxioCel®) in the management of post excision SCC wounds.

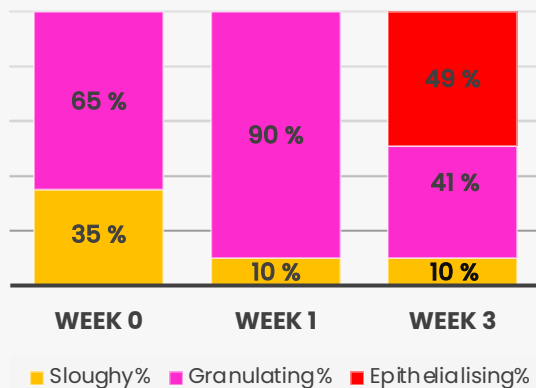
## METHOD

Case study series of two post excision wounds, with BMG dressing (MaxioCel) to reduce wound over-granulation, manage wound exudate, reduce odour and facilitate effective wound bed management.

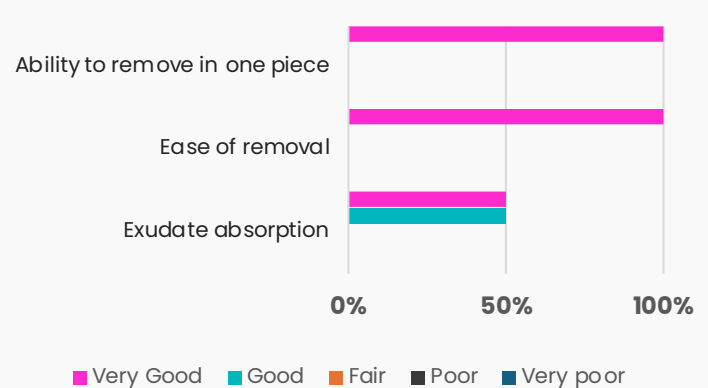
## RESULTS

- ✓ Non healing wound of a year's duration, a vast improvement was observed, after just 2.5 weeks of treatment leading to 100% granulation and almost complete closure at 6 weeks.
- ✓ Overall reduction in wound size and reduction of over-granulation observed.
- ✓ Managed biofilm and exudate. No adherence to wound bed. Medical Imagery supports these results.

Average Condition of Wound Bed  
(2 Wounds)



Overall performance ratings of MaxioCel

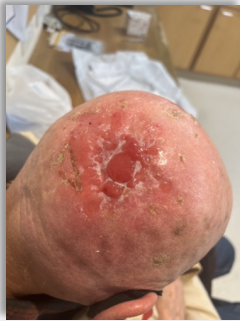

## CONCLUSION

Working in partnership with the Skin Integrity Team, the treatment aims were achieved. MaxioCel allowed full visibility of the wound bed in all cases and exceeded clinical expectations. Patient clinic visits reduced. Patients' wounds in this case study series are now better managed and the patients reported being more comfortable. We are now considering the inclusion of MaxioCel onto the specialist wound care formulary.

# CASE STUDIES

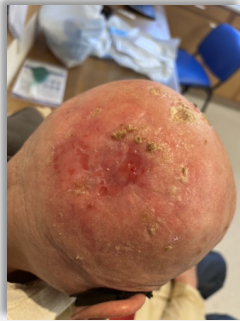## 84-year-old male patient



12.09.2023

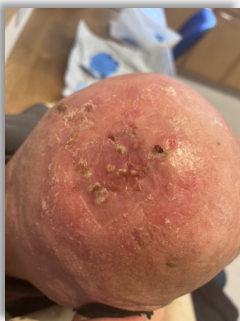An 84-year-old male presented with a non-healing wound post-excision of Squamous Cell Carcinoma on the scalp. The wound was 100% over-granulated and had been present for over a year.

Previous treatments included various primary and secondary dressings without success.



17.10.2023

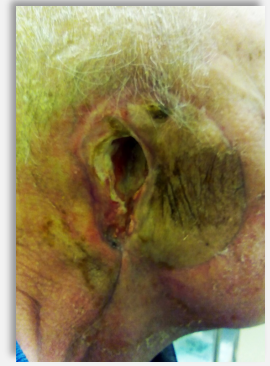The introduction of MaxioCel® as a primary dressing with a biofilm treatment pathway led to significant improvements. Within 2.5 weeks, the wound had markedly improved, with the patient and clinician expressing high satisfaction with the results. The wound was nearly healed after 6 weeks of MaxioCel treatment, leading to its consideration for the specialist formulary due to its effectiveness and potential health economic benefits.



14.11.2023

The patient's, who lived alone was independent in activities of daily living. Other factors such as atopic dermatitis, and Stage 3 CKD were present. Treatment goals were achieved, with MaxioCel's ease of use and effectiveness being particularly noted.

## 76-year-old male patient

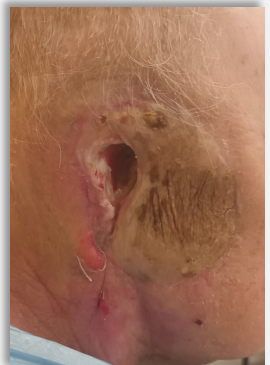

20.10.2023

A 76-year-old patient treated for a surgical wound 5.5 months post excision of Squamous Cell Carcinoma (SCC), involving a left parotidectomy and neck dissection. Patient lived alone.

The wound was initially managed with an alginogel (Flaminal®) and hydrofibre rope dressings (Urgoclean®). MaxioCel was adopted for its exudate management and autolytic debridement capabilities.

Over the evaluation period, the wound showed improvement with a reduction in slough and the emergence of healthy granulating tissue. The patient experienced no discomfort with dressing changes, and the clinician reported that



15.11.2023

MaxioCel was easy to use, and its one-piece removal and non-adherence to the wound bed was beneficial in this case.

The secondary dressing was changed from an adhesive foam dressing (Allevyn®) to a silicone foam (Biatain®) to better manage exudate. The clinicians plan to continue using MaxioCel and aim to have it added to the specialist formulary, noting the patient's satisfaction with the treatment.

## Key Clinical Benefits

1

**Rapid Healing Trajectory:** Significant improvement and healing seen in both cases, exceeding clinician expectations. The Initial concerns of treating two complex wounds was addressed by successfully managing biofilm and hyper-granulation, showcasing MaxioCel's effectiveness.

2

**Healing Achieved:** One wound almost healed by the final evaluation at 6 weeks, demonstrating MaxioCel's capability in facilitating complete recovery in challenging cases.

## Key Patient Benefits

1

**Reduced Dressing Size and Frequency:** The patient appreciated the transition to a lighter feeling dressing, enhancing comfort and convenience.

2

**Reduction of Regular Clinical Visits:** MaxioCel reduced the need for frequent clinic visits, which improved quality of life and satisfaction with the treatment process.