

MAXIOCEL-100% CHITOSAN WOUND DRESSING ON SCROTUM AND PERINEAL WOUND

Center

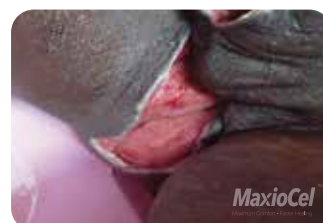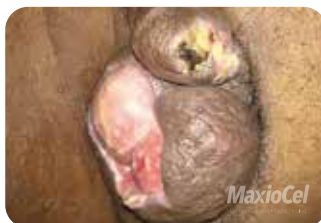- B.L.Kapoor Hospital-India: Dr. H.S Kapoor

Patient details	58 years , Male
Diabetes	Yes
Nicotine consumption	No
Localized infection	Yes
Nutritional status	Well nourished
Co-morbidities	Urinary tract infection
Current medication	Insulin,Ceftriaxone
Wound history	Wound perpetuating from a period of 1 month,Incision and drainage done along with regular debridements before repairing the dorsal slit of the penile area.Wound highly infected in spite of regular dressings.

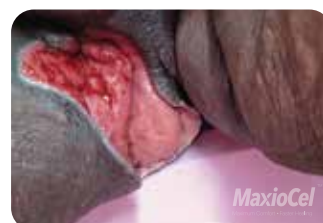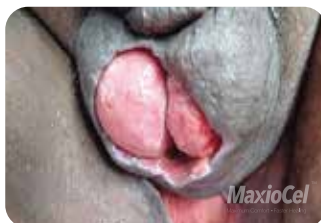Initial wound bed evaluation

Infection (Local Factors)	Yes	No	Exudate	Dry	Low	Medium	High	
Exudate	<input checked="" type="checkbox"/>	<input type="checkbox"/>	Levels	<input type="checkbox"/>	<input type="checkbox"/>	<input checked="" type="checkbox"/>	<input type="checkbox"/>	
Erythema	<input checked="" type="checkbox"/>	<input type="checkbox"/>						
Malodorous	<input checked="" type="checkbox"/>	<input type="checkbox"/>	Exudate	Watery	Cloudy	Thick	Purulent	Red
Pain	<input checked="" type="checkbox"/>	<input type="checkbox"/>	Type	<input type="checkbox"/>	<input checked="" type="checkbox"/>	<input type="checkbox"/>	<input type="checkbox"/>	<input type="checkbox"/>
Oedema	<input type="checkbox"/>	<input checked="" type="checkbox"/>						

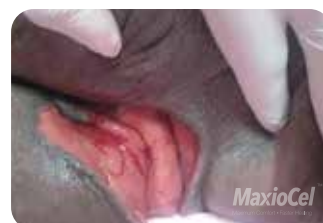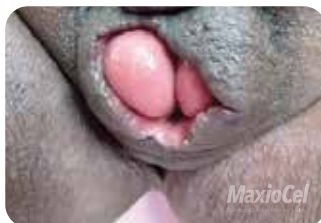Day-1



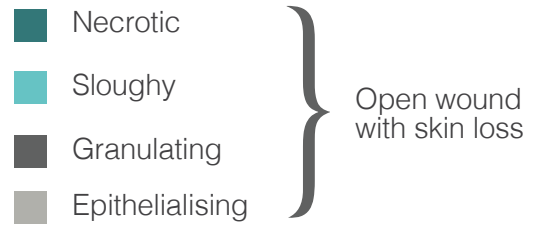
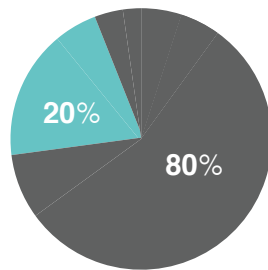
Day-4



Last day



Tissue type



Wound management goals

Parameters	Yes	No
Debridement		
Infection prevention		
Exudate management		
Optimum moisture maintenance		
Protect granulation tissue / Epithelializing tissue		

End report

No of MaxioCel dressings done	15
Frequency of MaxioCel dressings	Daily
MaxioCel variant used	MX1010 and MX2530
Final day wound condition	Wound infection significantly reduced in penile region, wound granulation and reduction in wound circumference can be seen. Exudate levels reduced to a great extent.

Result

Patient Outcome with MaxioCel	Ease of Application / Removal	Anti-microbial barrier	Wound adherence	Conformability	Wound scar improvement	Pain management
Excellent						
Good						
Fair						
Poor						

Discussion

- Fournier's gangrene is a sometimes life-threatening form of necrotizing fasciitis that affects the genital, perineal, or perianal regions of the body. It is serious condition that kills soft tissues, often quickly, including muscles, nerves, and blood vessels.
- It most commonly affects men, particularly in the scrotum or penis. Often, a variety of organisms will grow and infect the tissue. If severe, a doctor may have to remove tissue, such as all or part of the penis or testicles.
- In the shown case, the patient was suffering from an infected wound in the penile and scrotal region along with the surrounding region. The debridement, flushing and necessary treatment regimes were followed.
- The choice of advanced wound care dressing plays a major role as the chances of infection spread were very high.
- MaxioCel dressing regimen was initiated for wound packing and covering on a regular basis along with constant wound irrigations. Significant improvements were seen within a few dressings as wound size reduction can be seen in the scrotal region, reduction in exudate levels and desloughing in the penile region can also be seen in the wound images.