

MAXIOCEL-100% CHITOSAN WOUND DRESSING ON PLANTAR SURFACE WOUND

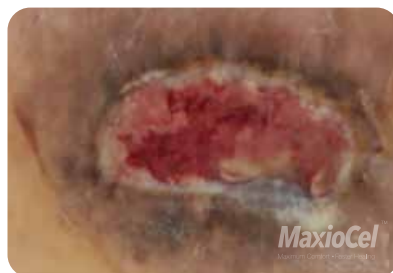Center

- Manipal Hospital, Bangalore-India: Dr. Venkatesh Reddy

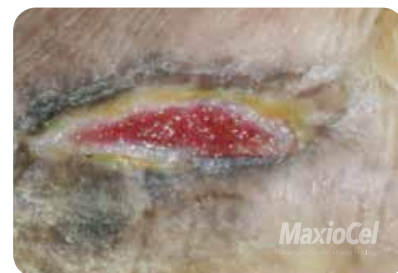Patient details	62 years , Male
Diabetes	Yes
Nicotine consumption	No
Localized infection	Yes
Nutritional status	Well nourished
Co-morbidities	None
Previous medication	Diabetic medication from 10 years, localised treatment with Saline and Gauze from past 3 months
Wound history	3 month old non healing chronic ulcer on left leg palm and metatarsal area, measurements being 6cmx3cmx0.5cm (Lengthxwidthxdepth)

Initial wound bed evaluation

Infection (Local Factors)	Yes	No	Exudate	Dry	Low	Medium	High	
Exudate	Yes	No	Levels			Medium		
Erythema	No	Yes						
Malodorous	Yes	No	Exudate	Watery	Cloudy	Thick	Purulent	Red
Pain	Yes	No	Type				Purulent	
Oedema	Yes	No						

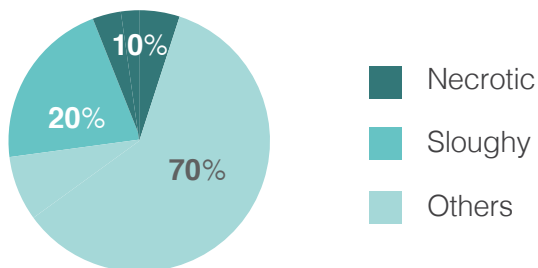


Wound before MaxioCel treatment



Wound after 12 days of MaxioCel treatment

Tissue type



Wound management goals

Parameters	Yes	No
Debridement	Yes	No
Infection prevention	Yes	No
Exudate management	Yes	No
Optimum moisture maintenance	Yes	No
Protect granulation tissue / Epithelializing tissue	Yes	No

End report

No of MaxioCel dressings done	6
Frequency of MaxioCel dressings	Alternate days
MaxioCel variant used	10x05cm
Final day wound condition	Granulated wound progressing towards epithelialisation, no signs of localised infection.

Result

Patient Outcome with MaxioCel	Ease of Application / Removal	Anti-microbial barrier	Wound adherence	Conformability	Wound scar improvement	Pain management
Excellent	Yes	No	No	Yes	Yes	Yes
Good	No	Yes	Yes	No	No	No
Fair	No	No	No	No	No	No
Poor	No	No	No	No	No	No

Discussion

- Increased plantar pressures and associated ulcers need to be treated by off-loading of the plantar surface. Useful off-loading mechanisms include reduction of walking speed, alteration of foot rollover during gait, and transfer of load from affected areas to other areas of the foot or the lower leg. These plantar off-loading mechanisms could result in an optimization of treatment.
- Wound treatment was done using MaxioCel for a period of 12 days, 6 dressings were done on alternative days. The wound circumference was significantly reduced along with healthy granulation.
- Overall, MaxioCel was found to be an excellent wound dressing in patients suffering from plantar surface wounds.