

Original Article

Effect of platelet-rich fibrin versus chitosan-based Axiostat hemostatic agent following dental extraction in cardiac patients on antiplatelet therapy: A comparative study

ABSTRACT

Background: Platelet-rich fibrin (PRF) is a biomaterial that promotes wound healing. It has a fibrinous matrix wherein platelets, pro-inflammatory cytokines, and various growth factors along with few cells are entrapped while Chitosan is a naturally occurring cationic biopolymeric material that is derived from an animal product, chitin. It has demonstrated biological properties which include acceleration in wound healing, hemostasis, enhancement of immunological response, mucosal adhesion by eliciting biological responses, and anti-microbial action.

Aim: The aim of this study was to evaluate the effect of PRF and Axiostat (A chitosan-based product) on hemostasis after tooth extraction among cardiac patients on antiplatelet medication.

Materials and Methods: This prospective study was carried out on 300 patients undergoing tooth extraction. Participants were divided into two categories ($n = 150$, respectively) as Group I (PRF dressing) and Group II (Axiostat dressing). Time to achieve hemostasis was observed using a stopwatch. Average pain score calculation was performed using visual analog on the 7-day postoperative period. Descriptive statistics were done, and data analysis was performed using the Mann-Whitney U-test. $P < 0.5$ and < 0.001 were considered statistically significant and extremely significant, respectively.

Results: Average pain score was 1.86 ± 0.06 in Group I and 1.05 ± 0.87 in Group II. Thus, lower postoperative pain was seen with Axiostat dressing. Hemostasis was achieved in Group II participants in 1.25 ± 0.06 min and in 1.89 ± 0.54 min in Group I. $P < 0.01$ was obtained, although no statistically significant difference in postoperative pain scores ($P = 0.8$) was seen.

Conclusion: Chitosan is a superior wound dressing material in achieving hemostasis in cardiac patients on antiplatelet medication after tooth extraction.

Keywords: Axiostat, cardiac, extraction, hemostasis, pain, platelet-rich fibrin

KAMALA RAJENDRA, SWETHA VEMPALLI¹, MITHILESWER KADIYALA², VIDUSHI SHARMA³, SWETHA KARIPINENI², SRIKANTH GUNTURU², DIPAK BALIRAM PATIL⁴

Department of Dentistry, ESICMC PGIMS Medical College, Rajajinagar, Bengaluru, Karnataka, ²Department of Oral and Maxillofacial Surgery, Drs. Sudha and Nageswara Rao Siddhartha Institute of Dental Sciences, Vijayawada, Andhra Pradesh, ³Department of Pharmacology, MMIMSR, Maharishi Markandeshwar (Deemed to be University), Mullana, Ambala, Haryana, ⁴Department of Dentistry, BKL Walawalkar Rural Medical College and Hospital, Chiplun, Maharashtra, India, ⁵College of Dentistry, Jazan University, Kingdom of Saudi Arabia

Address for correspondence: Dr. Vidushi Sharma, Assistant Professor, Department of Pharmacology, MMIMSR, Maharishi Markandeshwar (Deemed to be University), Mullana - 133 207, Ambala, Haryana, India.
E-mail: vidushi.dr@gmail.com

Received: 07 December 2020, **Revised:** 24 December 2020, **Accepted:** 16 April 2021, **Published:** 13 December 2021


INTRODUCTION

Platelets have an enucleated spherical or oval-shaped structure that contains granule. They have a diameter measured between 200 and 500 nm. These α -granules contain transforming growth factor- β (TGF- β), insulin-like growth factor-I, and platelet-derived growth factor (PDGF). The secretion of active proteinaceous components allows granular fusion with the cellular membrane of the platelets by their subsequent binding to transmembranous cell membranous receptors.^[1]

This is an open access journal, and articles are distributed under the terms of the Creative Commons Attribution-NonCommercial-ShareAlike 4.0 License, which allows others to remix, tweak, and build upon the work non-commercially, as long as appropriate credit is given and the new creations are licensed under the identical terms.

For reprints contact: WKHLRPMedknow_reprints@wolterskluwer.com

How to cite this article: Rajendra K, Vempalli S, Kadiyala M, Sharma V, Karipineni S, Gunturu S, *et al.* Effect of platelet-rich fibrin versus chitosan-based Axiostat hemostatic agent following dental extraction in cardiac patients on antiplatelet therapy: A comparative study. *Natl J Maxillofac Surg* 2021;12:361-6.

Access this article online	
Website: www.njms.in	Quick Response Code 
DOI: 10.4103/njms.NJMS_270_20	

Tooth extractions performed in patients with cardiac surgeries requiring placement of artificially made heart valves are placed under anti-coagulant therapy. These patients are at an increased risk of complications arising because of hemorrhage occurring postoperatively. Most commonly used anti-coagulant drugs include warfarin and acetylsalicylic acid.^[2]

Medications targeted against platelets are mainly aspirin (at a dosage of 75 mg to 300 mg), dipyridamole, and Clopidogrel. The drug combination of aspirin along with Clopidogrel results in an additive and synergistic effect due to their inhibitory effect on complementary pathways of the platelet pathway.^[3]

The international normalized ratio (INR) is commonly used to assess anti-coagulant control with a maximum value of 3.5 (range between 3 and 4). Stopping of anti-coagulation therapy and subsequent, replacement with heparin before a minor surgical procedure can result in thromboembolism. Various protocols have been proposed which include (a) combination therapy using anti-fibrinolytics and hemostatic agents, (b) no changes in the regular anti-coagulant therapy or by administering tranexamic acid as local anti-fibrinolytic agent, and (c) use of fibrin glue.^[2] Local hemostatic agents have been classified into (a) passive, (b) active, (c) fluids, and (d) sealants. Passive agents have been found to trigger the clotting cascade through absorption and aggregation while the active agents are found to contain clot components while it contains clot components while the remaining two classes include poly-ethylene glycol polymer, fibrin-containing adhesive, glutaraldehyde, cyanoacrylate, and albumin. They are also been classified on the basis of their mechanisms of action into (a) factors responsible for coagulating plasma, (b) fibrinolytic inhibitors, (c) agents causing vasoconstriction and which are pro-aggregation, (d) agents responsible for the stimulation of cellular aggregation along with adhesiveness, (e) agents responsible for causing denaturation of proteins, and (f) mixed pathways.^[4] There have been numerous hemostatic agents that are used for hemostasis, for example, collagen, oxidized regenerated cellulose, platelet-rich fibrin (PRF), etc.^[5]

The American College of Chest physicians have suggested that patients undergoing anti-coagulant therapy must discontinue the use of drug 5 days before any surgical intervention and bridge therapy utilizing the use of heparin should be initiated. However, in contrast, the American Heart Association has suggested that the INR should be reduced within a range of 2–2.5 with strict monitoring of INR. Harfoush *et al.* evaluated 50 patients with an INR value of ≤ 3.5 . Of these, 25 patients

constituted Group A in which the extraction sockets were packed with PRF, whereas Group B ($n = 25$) was treated with dry gauze packing. Eighty-percent of patients belonging to Group A had a moderate amount of bleeding seen in 28% cases, whereas 72% suffered from severe bleeding. Hence, it was concluded from the study that topical PRF application following the extraction of teeth in participants on warfarin therapy helped in achieving adequate hemostasis following the extraction of teeth.^[6]

The use of techniques that make the use of platelet concentrates is a simple yet optimal method.^[1] A first-generation platelet concentrate, platelet-rich plasma (PRP) was introduced by Marx in 1998. The disadvantage of PRP is that (a) there is no uniformity in the preparation technique, (b) it requires activation using bovine-origin thrombin, and (c) anti-coagulants have to be added.^[7,8] On the other hand, PRF is prepared by immediate centrifuging of venous blood. The serum obtained is termed as “hyper-acute serum” and has a high proliferative effect on bone marrow-derived mesenchymal stem cells, chondrocytes, and osteoblasts. However, despite the obvious regeneration causing effects, there are certain drawbacks which are as follows: (a) the PRF handling should be done in an open and sterile environment. This is most of the times impossible to achieve in an oral environment and (b) it does not have adequate tensile strength, hence, the material cannot be sutured.^[8]

Although due to legal restrictions, a second-generation concentrate of platelets was developed by Choukroun *et al.* in France in 2001 which is known as “PRF.” This biomaterial has no requirement of an anti-coagulant or a bovine origin thrombin. It is an autologous fibrinous matrix that contains the large quantities of cytokines derived from the platelets. It has been routinely used for the healing of hard along with soft tissues.^[2]

Autologous bone graft materials containing high concentrations of platelets such as the PRP and PRF. The PRP is an autologous platelet concentration which has been suspended within plasma and contains a variety of growth factors such as the PDGF, TGF- $\beta 1$ and - $\beta 2$, vascular endothelial growth factor (VEGF) while the PRF is a next-generation concentrated platelet product comprised leukocytes, glycoproteins, cytokines, and a fibrinous matrix.^[9] PRF influences three mechanisms that are involved in the process of wound healing: (i) angiogenesis (ii) immunological response, and (iii) proliferation of epithelium. It causes the release of elevated levels of three growth factors: PDGF-AB, VEGF, IL-1 β , and TNF- α (last two are pro-inflammatory cytokines).^[10] PRF is a bioactive wound dressing and has an advantage in

being of autogenous nature.^[11] The main factor responsible for obtaining a good quality PRF membrane is time elapsed between blood collection and centrifugation during which polymerization takes place due to the thrombin component. A network of fibrin is formed due to the transformation of soluble form of fibrin to insoluble fibrinous form. However, a significant disadvantage is the rapid degradation of the PRF membrane in a short time period when compared to the time taken for the healing of the bone.^[12]

Chitosan is a biopolymeric mucopolysaccharide with a structural resemblance to glycosamine which is an alkaline deacetylated chitin product. It is derived from crustacean exoskeletons.^[13] Biochemically, chitosan comprises of a high-molecular-weight polymer along with glucosamine and acetyl glucosamine when it is subjected to solubility in diluted acids (organic as well as inorganic). Chitosan has a number of biological properties due to its biocompatible, biodegradable, anti-bacterial, and easy degradation to glucosamine components.^[3] The biodegradable properties of chitosan result in the production of nontoxic oligosaccharides of variable lengths which can be processed in the different pathways of metabolism and can be excreted from the body. Structurally, chitosan is a nontoxic, bio-degradable complex carbohydrate chitin-derivative poly β (1-4)-N-acetyl D-glucosamine. It has lesser than 100% deacetylated content, which makes it a lesser co-polymer that contains both D-glucosamine and N-acetyl-D-glucosamine monomeric units. It exhibits mucoadhesive properties in its acidic salt form.^[14]

Preparations derived from chitosan have varying amount of molecular weights. Its properties include antimicrobial activities, hemostasis, healing, acting as a scaffold for tissue engineering and as systems for the delivery of drugs. One such commercially available product is HemCon bandage which is used for controlling bleeding of wounds. Chitosan is a positively charged material resembling sponge and bears a hemostatic property. Its mechanism of activity invokes attracting red blood cells and platelets (which have surface negative charge). Thus, using ionic interactions, chitosan forms a strong seal at the site of a surgical wound.^[2] Malette *et al.* demonstrated that a solution of chitosan led to the formation of coagulum when it comes in contact with blood.^[15] The anti-microbial effects of chitosan may be explained under the following mechanisms: (a) its binding with DNA through the protonated amino groups and (b) interaction with the negatively charged bacterial cell membrane.^[16]

The aim of the study was to compare the efficacies of PRF with chitosan-based Axiostat on controlling hemostasis

in the extraction sockets in cardiac patients undergoing antiplatelet therapy.

MATERIALS AND METHODS

This was a prospective study conducted on 300 participants who were indicated for the extraction of teeth. All the study participants had a medical history of cardiac disease and were on anti-platelet drug therapy. The inclusion criteria of the study were as follows: (1) Patients with an age range of 35–70 years, (2) patients with a INR value between 1 and 3.5, i.e., ≤ 3.5 , and (3) patients were nondiabetic. The exclusion criteria were as follows: (1) Patients who had to undergo more than one tooth extraction and (2) patient with known allergy to sea-foods.

The study participants were randomly divided into two groups containing equal numbers of participants, i.e., $n = 150$, each in Group I (PRF) and Group II (Axiostat), respectively. All patients underwent extractions after preventive antibiotic prophylaxis before extractions. For prophylactic measures, Amoxicillin in dose of 2 g by oral route was given prior to the procedure. A single operator performed the extraction procedure along with the placement of the selected hemostatic agent within the socket.

In Group I, PRF membrane was placed after preparing it in clean and sterile glass test tubes using centrifugation at 3000 rpm for 10 min. In Group II, commercially available Axiostat dressing was placed within an extraction site followed by the application of digital pressure for a duration of 30 s. After hemostasis was evident, the material was removed followed by irrigation with saline. Time to achieve hemostasis was noted using a stopwatch. All patients were provided with postextraction instructions and were asked to report in case of any postsurgical or operative bleeding was observed. Postextraction healing of soft-tissue changes was observed on the 7th postoperative day. The average pain score was calculated using a Visual Analog Scale from 1 to 10 after seven days of postoperative period.

Descriptive analysis was done after entering all the collected data in Microsoft Excel sheets and the statistical tool used for analyzing data was Mann–Whitney U-test. $P < 0.5$ and 0.001 were set as significant and extremely significant, respectively.

Ethical approval

This study was conducted in compliance with the protocol; ethical approval was obtained from the Institutional Ethical Committee (IEC/IC26/2020).

RESULTS

The average pain score was found to be 1.86 ± 0.06 in Group I when compared to 1.05 ± 0.87 in Group II; therefore, with slightly lower postoperative pain in Axiostat treated group [Graph 1]. Complete hemostasis was achieved in Group II participants (extraction sockets were packed with Axiostat) in 1.25 ± 0.06 when compared to Group I (PRF-treated extraction site) with a mean \pm standard deviation value of 1.89 ± 0.54 [Graph 2]. A statistically significant value of $P < 0.01$ was obtained on comparing both the groups. However, in this study, no statistically significant difference in postoperative pain ($P = 0.8$) was observed [Table 1].

DISCUSSION

In the current study, complete hemostasis was seen to be achieved earlier in chitosan-based wound dressing compared to the extraction socket site which was packed with PRF and a statistically significant P value (<0.01) was obtained on comparison of both groups. Although no statistically significant difference in the postoperative pain was observed, the study findings are corroborated by a study conducted by Sarkar *et al.* who compared the efficacy of PRF and Chitosan hydrogel in 60 patients who were on oral anti-platelet medication therapy. The time in which hemostasis was achieved was noted. It was seen that in extraction sites which were treated with platelet enriched fibrin, bleeding stopped

in 2.64 min while in the group treated with Axiostat, arrest of bleeding was seen in 1.182 min. There was a statistically significant difference in the time of stoppage of bleeding between both the comparison groups studied ($P < 0.0001$). The postoperative pain was found to be lesser in sites treated with PRF when compared to Axiostat hydrogel.^[17]

In the present study, Chitosan was found to be a superior wound dressing material in achieving hemostasis in cardiac patients on antiplatelet medication after tooth extraction and these results were in accordance with the study conducted by Seethamsetty *et al.* who evaluated that surgical sites treated with Chitosan-based dressings had better hemostatic effects along with lower pain as compared to the control group.^[18] Supportive findings have been reported by Malmquist; however, their findings did not show any statistical significance. An interesting observation made was that if an extraction socket was fully packed, there was an increase in pain due to residual unreactive acetic acid.^[19]

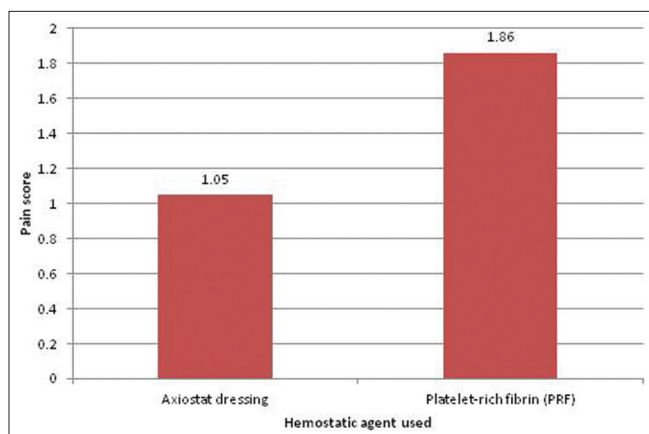
Larik *et al.* compared the effectiveness of PRF with Tranexamic acid in 84 patients. These materials were tested after placement within extraction sockets. 97.6% efficacy in patients (41//42) of Group A was seen, whereas 92.86% patients in Group B demonstrated clinical effectiveness. No statistical significance with a P value of 0.306 was seen.^[20]

Bhujbal *et al.* in a split-mouth study which was performed on 20 study participants who underwent bilateral mandibular third molar extractions compared PRF treated sites with normal controls. Healing of soft tissues was evaluated immediately, first, third, and 7 days of the postoperative period, whereas bone density was measured using radiographic assessment. On the 3rd- and 6th-month postoperative follow-ups, postoperative swelling was found to be statistically significant in the immediate period,

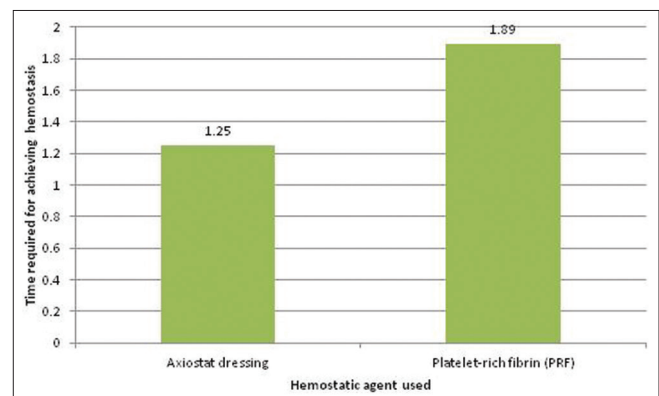
Table 1: Parameters studied and their P values

Hemostatic agent used	Mean \pm SD	
	Pain scores	Time taken for complete hemostasis
Axiostat dressing	1.05 ± 0.87	1.25 ± 0.06
PRF	1.86 ± 0.06	1.89 ± 0.54
P obtained	0.8	0.001

PRF: Platelet-rich fibrin, SD: Standard deviation



Graph 1: Graph demonstrating pain score values in both the dressings used



Graph 2: Graph demonstrating time required for hemostasis

1st, 3rd, and 7th days ($P < 0.15$, < 0.58 and < 0.78 , respectively) but no significance was obtained on day 7 ($P < 0.00$). The postoperative healing of the soft and hard tissues was seen in the PRF site.^[6]

Sinha *et al.* evaluated the efficacy of Axiostat on 50 patients with cardiac medical history disease without any alteration or stoppage of anti-platelet drug therapy. The average time taken hemostasis was 1.5 min in cases with prolonged bleeding.^[3] The self-adhesive property of Axiostat is mainly because of electrostatically driven binding of the red blood cells to the chitosan component of the Axiostat dressing by the formation of a densely packed viscous material which by itself acts as a pressure pack within an extraction socket. The poly-cationic property of this chitosan-based dressing material at an acidic pH helps it in causing disruption of cell membranes of Gram-negative bacteria.^[3]

Sharma *et al.* examined a total of forty participants who were on anti-platelet medication. The split-mouth study design was applied with the sites of extractions categorized into: (a) Group 1: those participants receiving Axiostat dental dressing (study group) and (b) Group 2: Participants with the conventional method of wound dressing using a sterile gauze pack with biting force and suturing was done, if it was indicated. It was observed that sites of extraction which were treated with Axiostat attained hemostasis in the lesser time period (mean period = 1 min 13 s) when compared to the control (mean = 14 min 1 s). A statistically significant difference ($P < 0.0001$) was observed between the time of hemostasis and postoperative pain along with better healing ($P < 0.0001$).^[21]

Kale *et al.* evaluated the efficacy of a HemCon dental dressing for control of bleeding from pos-extraction sockets. It was found that extraction sockets treated with HemCon achieved hemostatic control in a mean period of 53 s when compared with controls with a mean period of 918 s. This was having a statistical significance of a P value of 0.001. Roughly, 72.5% of extraction sites treated with this dressing demonstrated better healing in the postoperative period with a statistical significance of a $P < 0.001$. In addition, it was observed that this material showed better results in sites with active bleeding.^[22]

Eldinbury in his study on 20 patients undergoing tooth extraction compared PRF dressing (Group A) with HemCom Dressing (Group B). Complete achievement of hemostasis was found in both the groups and no delay in bleeding was observed. Participants belonging to Group A demonstrated very less pain and an accelerated rate of healing while those in Group B exhibited moderate-to-severe pain in the first few

days after the extraction procedure along with retardation of the healing process.^[2] Similar findings were also reported by Fradet *et al.* who observed that grafts treated with chitosan were impermeable to blood flow.^[23]

De Almeida Barros Mourão *et al.* in their study reported a mean time for achieving hemostasis as 10.3 ± 2.5 s.^[24] An interesting observation was made by a comparative study between collocate (a collagen dressing) and PRF by Sharma *et al.* They concluded that both of these materials cause an acceleration in the wound healing process and a significant reduction in pain as well.^[25]

CONCLUSION

In this study, Axiostat has been demonstrated to have effective value in lowering bleeding time among postextraction cases in patients on anti-platelet therapy. Furthermore, a reduction in the postoperative pain and comorbid conditions were seen which has been supported by various investigators. Hence, it can be concluded that chitosan-derived wound dressings have better results in the healing of extraction sockets.

Financial support and sponsorship

Nil.

Conflicts of interest

There are no conflicts of interest.

REFERENCES

1. Khiste SV, Tari RN. Platelet-rich fibrin as a biofule for tissue regeneration. ISRN Biomat 2013;1-6. [doi: 10.5402/2013/627367].
2. Eldibany RM. Platelet rich fibrin versus Hemcon dental dressing following dental extraction in patients under anticoagulant therapy. Tanta dent J 2014;11:75-84.
3. Sinha N, Mazumdar A, Mitra J, Sinha G, Baunthiyal S, baunthiyal S. Chitosan based axiostat dental dressing following extraction in cardiac patients under antiplatelet therapy. Int J Oral Health Med Res 2017;3:65-7.
4. Budko EV, Chernikova DA, yampolsky LM, Yatsyuk VY. Local hemostatic agents and ways of their improvement. Biol Herald 2019;27:274-85.
5. Belkhede SG, Salaria SK, Aggarwal R. Comparative evaluation of the platelet-rich fibrin bandage versus gelatin sponge-assisted palatal wound healing of free gingival graft donor site: A case series. J Indian Soc Periodontol 2019;23:589-92.
6. Harfoush M, Boutros E, Al-Nashan A. Evaluation of topical application of platelet rich fibrin (PRF) in homeostasis of the bleeding after teeth extraction in patients taking warfarin. Int dent J St Res 2016;4:144-7.
7. Naik B, Karunakar P, Jayadev M, Marshal VR. Role of platelet rich fibrin in wound healing: A critical review. J Cons Dent 2013;16:284-94.
8. Kardos D, Hornyák I, Simon M, Hinsenkamp A, Marschall B, Várdai R, *et al.* Biological and mechanical properties of platelet-rich fibrin membranes after thermal manipulation and preparation in a single-syringe closed system. Int J Mol Sci 2018;19:3433-47.
9. Bhujbal R, Veerabhadrapa SK, Yadav S, Chappi M, Patel V.

- Evaluation of platelet-rich fibrin and platelet-rich plasma in impacted mandibular third molar extraction socket healing and bone regeneration: A split-mouth comparative study. *Eur J Gen Dent* 2020;9:96-102.
10. Jain V, Triveni MG, Kumar AB, Mehta DS. Role of platelet-rich-fibrin in enhancing palatal wound healing after free graft. *Contemp Clin Dent* 2012;3:S2401-1.
 11. Gür ÖE, Ensari N, Yılmaz NDS. The effects of platelet-rich fibrin membrane on secondary healing after pleomorphic adenoma excision in the hard palate: A preliminary study. *Ann Maxillofac Surg* 2017;7:78-81.
 12. Aktas A, Ozer T, Sen M, Turk M, Karabulut E. Comparison of the mechanical properties of platelet-rich fibrin and ankaferd blood stopper-loaded platelet-rich fibrin. *Niger J Clin Pract* 2018;21:1087-92.
 13. Rao SB, Sharma CP. Use of chitosan as a biomaterial: Studies on its safety and hemostatic potential. *J Biomed Mater Res* 1997;34:21-8.
 14. Pusateri AE, McCarthy SJ, Gregory KW, harris RA, cardenas L, McManus AT, *et al.* effect of a chitosan-based hemostatic dressing on blood loss and survival in a model of severe venous hemorrhage and hepatic injury in swine. *J Trauma* 2003;54:177-82.
 15. Malette WG, Quigley H, Gaines RD, Johnson ND, Raines G. "Chitosan": A new hemostatic. *Ann Thoracic Surg* 1983;36:55-8.
 16. Maksym PV. Chitosan as a hemostatic agent: Current state. *Eur J Med* 2015;24-33. [doi: 10.13187/ejem.s.b 2015.2.24].
 17. Sarkar S, Prashanth NT, Shobha ES, Rangan V, Nikhila G. Efficacy of Platelet Rich Fibrin versus chitosan as a hemostatic agent following dental extraction in patients on antiplatelet therapy. *J Oral Biol Craniofac Res* 2019;9:336-9.
 18. Seethamsetty S, Sarepally G, Sanober A, Qureshi Y, Fatima U, Arif SM. A comparative evaluation of the effectiveness of chitosan-based dressing and conventional method of hemostasis in patients on oral antithrombotic therapy without therapy interruption. *J Pharm Bioallied Sci* 2019;11:S18-23.
 19. Malmquist JP, Clemens SC, Olen HJ, Wilson SL. Hemostasis of oral surgery wounds with the HemCon dental dressings. *J Oral Maxillofac Surg* 2008;66:1177-83.
 20. Larik MD, Hassan SG, Majeedano SA, Rajper WA, Waq AS, Akro B, *et al.* Hemostatic effect of platelet rich fibrin versus Tranexamic acid after tooth extraction in patients under anticoagulant therapy. *Open Access J Biomed Sci* 2020;2:404-7. [doi: 10.38125/OAJBS.00187].
 21. Sharma S, Kale TP, Balihallimath LJ, Motimath A. Evaluating effectiveness of axiostat hemostatic material in achieving hemostasis and healing of extraction wounds in patients on oral antiplatelet drugs. *J Contemp Dent Pract* 2017;18:802-6.
 22. Kale TP, Singh AK, Kotrashetti SM, Kapoor A. Effectiveness of HemCon dental dressing versus conventional method of hemostasis in 40 patients on oral antiplatelet drugs. *Suktan Qaboos Univ Med J* 2012;12:330-5.
 23. Fradet G, Brister S, Mulder DS, Lough J, Averbach BL. Evaluation of chitosan as a new hemostatic agent: *In vitro* and *in vivo* experiments. *Chitin Nat Technol* 1986;4:443-5.
 24. deAlmeida Barros Mourão CF, Calasans-Maia MD, de Mello Machado RC, de Brito Resende RF, Alves GG. The use of platelet-rich fibrin as a hemostatic material in oral soft tissues. *Oral Maxillofac Surg* 2018;22:329-33.
 25. Sharma V, Kumar A, Puri K, Bansal M, Khatri M. Application of platelet-rich fibrin membrane and collagen dressing as palatal bandage for wound healing: A randomized clinical control trial. *Indian J Dent Res* 2019;30:881-8.